

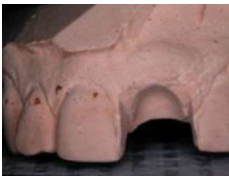Construction of Immediate Removable Appliances

Transitional appliances (Flippers and Essix Appliances) are convenient and esthetic immediate replacements for extractions in the esthetic zone. Careful, atraumatic extraction will preserve the hard and soft tissues to optimize the esthetics of the final restoration. Bone grafts are typically placed for site development in anticipation of implant placement.

An often overlooked role of the removable appliance is the preservation and development of the soft tissue contour.

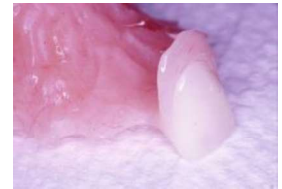Common Mistakes

Two common mistakes in the construction of the appliances are indenting the cast and the creation of a labial flange. These not only impinge on the surgical area, but they also miss the opportunity to develop the emergence profile.



Indenting the cast causes the restoration to be placed directly into the surgical area, disrupting the healing .

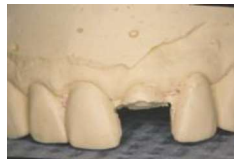A labial flange not only infringes on the surgical area but it also makes it difficult to see the surgical area during placement.



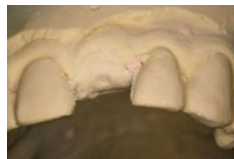Recommended Construction



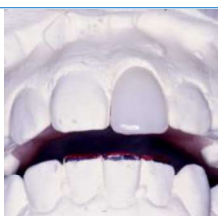Step 1- Identify the level of the interproximal papillae. This ensures that the restoration will not press on the most delicate part of the surgery.



Step 2- Remove the tooth to the level of the interproximal tissue. Always keeping the restoration away from the tissue.

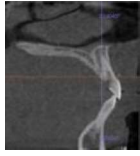
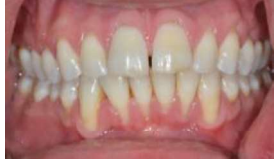
Step 3- Remove the rest of the tooth, leaving a slight convexity. This prevents the restoration from pressing on the surgical area.



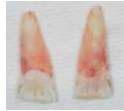
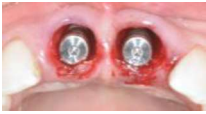The restoration replaces the missing tooth while only slightly touching the marginal tissue. Post-surgical swelling shapes the tissue to the contour of the restoration.

Case Reports

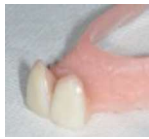
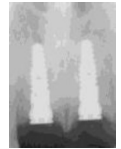
Thirty year old male. Teeth #'s 8 and 9 have external resorption and need to be removed. The patient will also be undergoing orthodontic treatment. He originally had orthodontics in his teens, but there has been relapse.

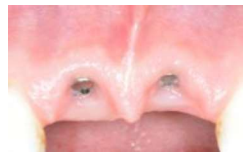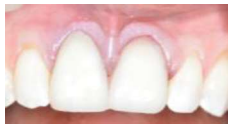Treatment Sequence



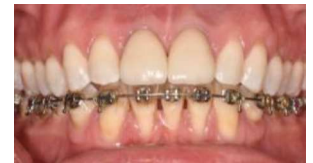The teeth are atraumatically removed and implants are placed along with bone grafts. Because of active orthodontic therapy, the implants were not temporized at the time of placement.



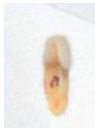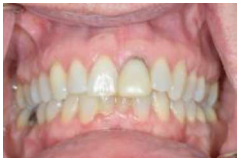Day of surgery



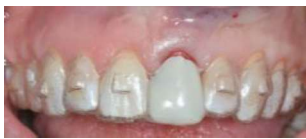Six months



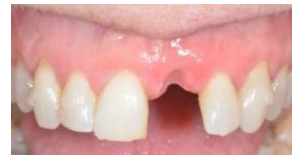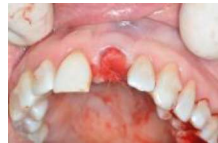Final restoration



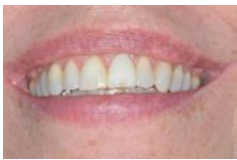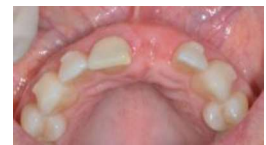Fifty-two year old female. Tooth #9 required extraction due to external resorption. The area is grafted along with membrane placement. The tooth is embedded into the clear aligner in the manner previously described.



Day of surgery



Six months



Final restoration

Final Comments

- Removable appliances are useful for immediate esthetic replacement.
- The key is to preserve the soft tissue profile in the cast.
- Removable appliances can also be used to develop the soft tissue profile in the final restoration.

perioimplantchicago.com

Peter O. Cabrera, DDS
939 W. North Ave. Suite 700
Chicago, IL 60642
312-944-7939

Bahareh Sabzehei, DDS, MS
Diplomate, American Board of
Periodontology and Implant Surgery