CONNECTIVE TISSUE GRAFTING:

AN OPTION IN RECONSTRUCTIVE PERIODONTAL SURGERY

PETER O. CABRERA, D.D.S.

In the past decade, reconstruction of damaged periodontal tissue has taken on an increasingly important role in surgical periodontics. Plastic surgery has served as a source of information on refined surgical techniques and wound healing. It is because of the similarity of reconstructive periodontal surgery to the medical specialty that many clinicians have referred to these refined approaches as "periodontal plastic surgery."

Recent emphasis on periodontal reconstruction coincides with restorative dentistry's emphasis on esthetics. Although the emergence of excellent bonding agents has amplified restorative possibilities, bonding alone cannot address mucogingival defects. The restorative dentist should consider reconstructing damaged periodontal structures before recommending cosmetic bonding or altering pontic design.

In cases of gingival recession, periodontal root coverage procedures can create a naturally esthetic result that will blend with the adjacent tissue. Ideal results can be obtained with the replacement of lost periodontal tissues followed by bonding of any residual defects. The two go hand in hand, enhancing our ability to restore form and function in a manner not possible before.

ABSTRACT

Connective tissue grafting offers an attractive option in periodontal reconstruction. The advantages and applications of this procedure are discussed.

The development of the connective tissue graft has significantly improved treatment options and predictability. This article addresses the current status of the connective tissue graft in periodontal surgery.

APPROACHES TO RECONSTRUCTION

For many years, the free gingival graft served as the principal approach in reconstructive gingival surgery.[1,2] Although it is a useful technique and many clinicians have obtained remarkable results in both root coverage and ridge augmentation,[3-5] the free gingival graft has definite limitations.

The greatest limitation involves survival of the donor tissue. On removal from the palate, the blood supply to the tissue is severed and the graft relies on the recipient site for nourishment. This limits the application of the free gingival graft in avascular areas, for example, during root coverage procedures.

A second limitation concerns esthetics. An exact color blend may be difficult to obtain in areas of cosmetic importance such as the maxillary anterior segment.

Finally, the resulting palatal denudation can be very uncomfortable, thus limiting patient acceptance

To avoid some of these limitations, another surgical approach can be used—the pedicle graft. The principal benefit of the pedicle graft is preservation of the blood supply, which enhances graft survival. In addition, the patient is spared the discomfort and inconvenience of two surgical sites.

However, there is rarely enough attached gingiva adjacent to the surgical site to complete most reconstructive applications. Also, dissection of attached gingiva from adjacent teeth can cause recession of the donor site.

Other procedures such as the coronally positioned flap and the semilunar coronally

Figure 1. Harvesting the connective tissue graft. Note the reflected flap.

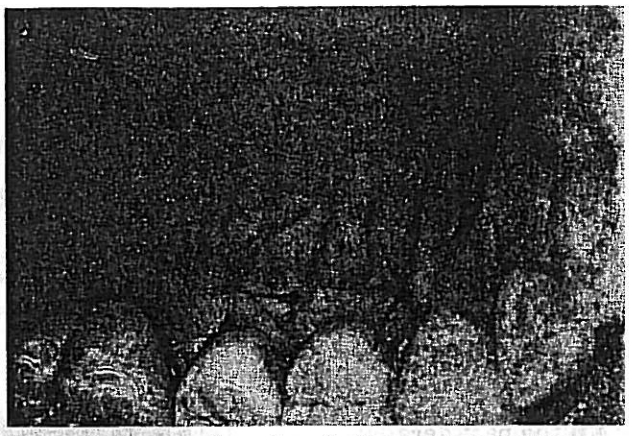

Figure 2. Donor site sutured after retrieval of the graft. Healing by primary intention.

positioned flap have similar drawbacks and thus limited applications.[6,7]

Some clinicians have used the free gingival graft to add attached tissue to an area before using a coronally positioned or lateral flap.[8,9] Although effective, this approach requires two surgical procedures and involves the disadvantages of the free gingival graft.

The connective tissue graft offered periodontists a predictable procedure for soft tissue reconstruction that did not have the limitations discussed above.

In 1974, Edel first described a subepithelial connective tissue graft performed to increase the width of keratinized gingiva.[10] In 1980 and again in 1982, Langer and Calagna reported use of this approach in rebuilding edentulous ridges.[11,12] In 1983, Langer and Langer discussed using the connective tissue graft to cover exposed root surfaces.[13]

Although there have been several modifications in the surgical procedure,[14-17] Langer and Langer are largely credited with the refinement and application of the connective tissue graft in periodontics.

In a recent study, Jahnke and others treated paired defects with both free gingival and connective tissue grafts.[18] They concluded that the connective tissue graft provided significantly greater root coverage than the free gingival graft. In equal situations, the connective tissue graft appears to be the treatment of choice in root coverage.

APPLICATIONS

The connective tissue graft can be considered a combination of the free gingival and the pedicle grafts. The clinician takes advantage of the sandwich technique in which the graft is interposed between the underlying connective tissue and the overlying flap. This technique allows the graft to receive nourishment from both surfaces.

The principal applications of the connective tissue graft include:

- root coverage with specific applications in cases of esthetic concern, progressive recession, recession where marginal tissue inhibits hygiene, root sensitivity and increased risk of root caries;
- edentulous ridge augmentation or recontouring before restorative therapy;
- gingival augmentation in conjunction with orthodontics or restorative dentistry;
- tissue buildup around implants to enhance esthetics.

The need for a broad zone of attached gingiva in preserving periodontal health has been questioned.[19,20] There is, however, a general agreement among experienced clinicians that in areas of Class V restorations or subgingival crown preparation, an adequate zone of attached gingiva is important.[21,22]

Reports have addressed the importance of attached tissue in orthodontic cases.[23-25] This is of particular relevance for

Continued on page 733

Continued from page 730

patients who have minimal or no attached gingiva with roots that are prominent in the bone or will be moved to a prominent position by orthodontics.

CLINICAL DESCRIPTION

Surgical variations of the connective tissue graft have been adequately described elsewhere.[13-17] A general synopsis is included for orientation.

Donor tissue. Regardless of the final destination, the connective donor tissue is generally secured from the palate after reflection of a partial thickness flap from the premolar-molar region.

To minimize surgical trauma, some surgeons omit the vertical incisions. However, in my experience, omitting these incisions can limit the direct visual access—making it difficult to determine the dimensions of the graft. The palatal flap typically will be closed by primary intention.

The thickness of the tissue procured depends on the intended use. For root coverage, 1.5 to 2 millimeters is adequate. Ridge augmentation procedures require a much thicker graft. Some fatty or glandular tissue may be included in the graft, which generally is not a problem.

The donor connective tissue also can be obtained from a distal wedge or the internal part of a palatal flap when done in conjunction with the grafting procedure.

Recipient site. There generally are two types of recipient sites:

- sites requiring root coverage or an increased zone of attached gingiva;
- sites requiring soft tissue buildup.

In cases requiring root coverage or an increased zone of attached gingiva, the affected roots should be thoroughly planed to provide a smooth, clean surface and reduce convexity. Some clinicians recommend application of citric acid or tetracycline to detoxify the root and exposed connective tissue fibers.[16] Others have reported equally good results without chemical root preparation.[13]

In cases of gingival augmentation without recession, root preparation is not necessary. A partial thickness flap is reflected around the teeth to be grafted. The connective tissue graft then is sutured to the line angles beyond the margins of the root. Finally, the flap that had been reflected is used to cover the graft. This procedure allows the graft to receive its blood from the underlying con nective tissue and the overlying flap.

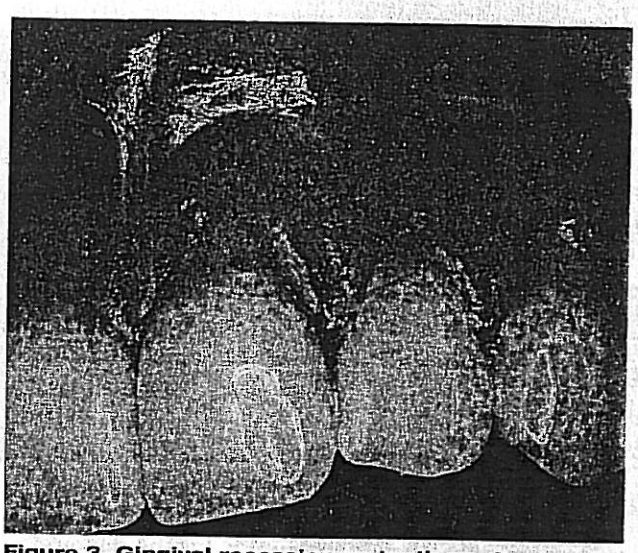

Figure 3. Gingival recession on tooth no. 9.

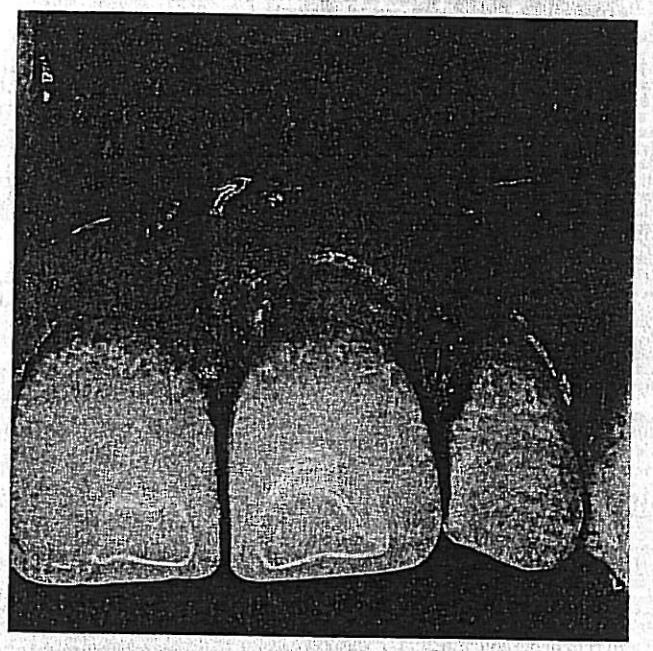

Figure 4. Connective tissue graft with overlying flap sutured in place.

Predictable root coverage can be anticipated on roots without significant interproximal loss of attachment, those classified as Class I and II in Miller's classification.[26] Root coverage becomes increasingly less predictable in areas with interproximal bone loss—Classes III and IV in Miller's system.

The sandwich technique also is used for soft tissue buildup. During ridge augmentation, the periosteum and connective tissue are preserved as a blood supply source. The area to be

augmented is prepared with a partial thickness flap or tunneling procedure. The connective tissue graft is sutured in place, then covered with the original flap. Care must be taken to remove all epithelium from the donor site.

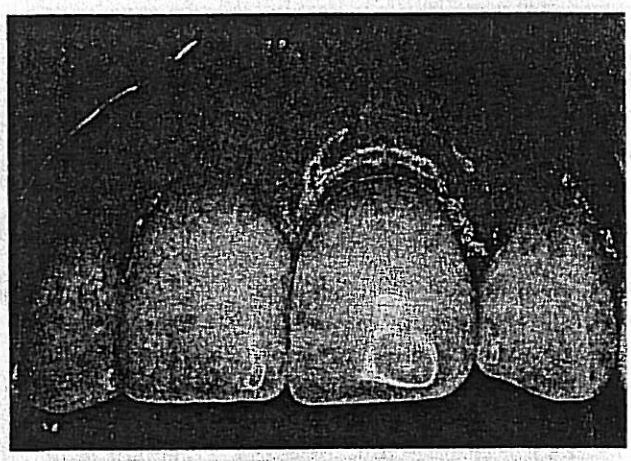

Figure 5. Final healing of connective tissue graft on tooth no. 9 six months after surgery.

HEALING

Because the graft receives nourishment from two surfaces, survival is high. Also, the color blend is usually excellent, which is an important esthetic consideration.

In the donor site, we are dealing with a palatal flap rather than exposed connective tissue as with free gingival grafts. Healing is mainly by primary intention and postoperative discomfort is dramatically decreased when compared to the free gingival graft.

In my experience, the connective tissue graft undergoes significant remodeling during the first few weeks after surgery. The initial superficial irregularities become smoother and more esthetically pleasing within weeks. However, it is wise to inform patients that soft tissue-plasty may be required for ideal esthetics. Depending on the desired results, this may be accomplished with a surgical blade, rotary diamond or a laser.

In patients with thin palatal tissue or palatal exostoses, available tissue can be limited. When there is limited connective tissue, an alternate procedure may be needed.

Although we don't know the exact histologic attachment between the root and the new tissue, it is rare to have any appreciable probing depth in properly selected cases of root coverage.

DISCUSSION

A deformed maxillary anterior ridge resulting from trauma or extraction of periodontally compromised teeth challenges the restorative dentist. Pontic elongation or masking with pink acrylic have limited benefits and can serve as plaque and food traps. Surgical approaches such as buildup with hydroxylapatite or onlay grafts also have their own limitations.

Connective tissue grafting has the advantages previously outlined plus it allows the periodontist the opportunity to reshape the soft tissue for maximum esthetics during ridge augmentation.

Although not all exposed roots require treatment, areas of recession without attached gingiva deserve special attention. This is particularly

true if one or more of the following is a factor:

- marginal gingival inflammation where the tissue contour makes hygiene difficult;
- root sensitivity;
- superficial root decay;
- intracrevicular restoration;
- orthodontic advancement;
- esthetic requirements.

There have been conflicting reports in the literature regarding the importance of attached gingiva in periodontal health.[19-25] Reasonable clinicians would disagree with any extreme view in always recommending treatment or not. Rather, recommendations should be based on each patient's circumstances and needs.

Among the factors to be considered are the severity and duration of the problem, patient habits, potential contributing factors such as subgingival restorations or orthodontic movement and thorough evaluation of treatment alternatives. If the patient opts for no treatment, he or she should understand that treatment alternatives and predictability may be compromised if the problem worsens.

Dr. Cabrera is a faculty member at Northwestern University Dental School and affiliate staff, Children's Memorial Hospital, Chicago. He also has a practice limited to periodontics, 990 W. Fullerton Pkwy., Suite 470, Chicago, Ill. 60614. Address reprint requests to Dr. Cabrera.

Recently, we have seen significant advances in the area of adhesive dentistry or dentin bonding. However, dentin bonding cannot reproduce the functional and esthetic characteristics of soft tissue. This is particularly true in cases of single tooth recession where contour and harmony are essential for optimal esthetics. Once a restoration has been placed on the root, soft tissue grafting becomes difficult without extensive root preparation. Also, in cases of progressive recession, additional loss of attachment can negate the esthetic results of the restorative therapy. Therefore, it is in the patient's best interest to include reconstructive periodontal surgery as a principal option in cases of recession. Connective tissue grafting has expanded our options in this area.

CONCLUSION

Connective tissue grafting is a useful approach in soft tissue reconstructive surgery. Procurement of donor tissue via a palatal flap, a key feature of this technique, is less traumatic than typical means of tissue harvesting. Also, the double blood supply used during connective tissue grafting increases predictability and enhances esthetics.

This procedure can be used for mucogingival reconstruction around the teeth and edentulous ridge augmentation and recontouring. ■

The opinions expressed or implied are strictly those of the author and do not necessarily reflect the opinion or official policies of the American Dental Association.

The author thanks Dr. Bradford Eschler for his expert assistance during the preparation of this article.

1. Sullivan HC, Atkins JH. Free autogenous gingival grafts. I. Principles of successful grafting. Periodontics 1968;6:121.
2. Sullivan HC, Atkins JH. Free autogenous gingival grafts. III. Utilization of grafts in the treatment of gingival recession. Periodontics 1968;6:152.
3. Miller PD. Regenerative and reconstructive periodontal plastic surgery. Dent Clin North Am 1988;32(2):287.
4. Seibert JS. Reconstruction of deformed, partially edentulous ridges, using full thickness onlay grafts. Part I. Technique and wound healing. Compend Cont Educ Dent 1983;4:437.
5. Holbrook T, Oschenbein C. Complete coverage of denuded root surface with a one-stage gingival graft. Int J Periodontics Restorative Dent 1983;3:9.
6. Bernimoulin JP, Luscher B, Muhlemann HR. Coronally repositioned periodontal flap. J Clin Periodontol 1975;2:1.
7. Tarnow DP. Semilunar coronally repositioned flap. J Clin Periodontol 1986;13:1982.
8. Maynard JG. Coronally positioning of a previously placed autogenous gingival graft. J Periodontol 1977;48:151.
9. Caffesse RG, Guinard EA. Treatment of localized gingival recession. Part IV. Results after three years. J Periodontol 1980;51:167.
10. Edel A. Clinical evaluation of free connective tissue grafts used to increase the width of keratinized gingiva. J Clin Periodontol 1974;1:185.
11. Langer B, Calagna LJ. Subepithelial graft to correct ridge concavities. J Prosth Dent 1980;44:363.
12. Langer B, Calagna LJ. The subepithelial connective tissue graft. A new approach to the enhancement of anterior cosmetics. Int J Periodontics Restorative Dent 1982;3:23.
13. Langer B, Langer L. Subepithelial connective tissue graft technique for root coverage. J Periodontol 1983;56:175.
14. Raetzke PB. Covering localized areas of root exposure employing the "Envelope technique." J Periodontol 1985;56:397.
15. Nelson SW. The subpedicle connective tissue graft. A bilaminar reconstructive procedure for the coverage of denuded root surfaces. J Periodontol 1987;58:59.
16. Journee D. Partially buried connective tissue grafts for gingival recession: Clinical results apropos of 22 cases. J Periodontol 1989;8:339.
17. Harris RJ. The connective tissue and partial thickness double pedicle graft: A predictable method of obtaining root coverage. J Periodontol 1992;63:477.
18. Jahnke PV, Sandifer JB, Gher ME, Gray JL, Richardson AC. Thick free gingival and connective tissue autografts for root coverage. J Periodontol 1993;64: 315.
19. Wennstrom J, Lindhe J, Nyman S. Role of keratinized gingiva for gingival health. A clinical and histological study of normal and regenerated gingival tissue in dogs. J Clin Periodontol 1981;8:311.
20. Miyasato M, Crigger M, Egelberg J. Gingival condition in areas of minimal and appreciable width of keratinized gingiva. J Clin Periodontol 1977;4:200.
21. Ericsson I, Lindhe J. Recession in sites with inadequate width of the keratinized gingiva. An experimental study in the dog. J Clin Periodontol 1984;11:95.
22. Maynard JG, Wilson RDK. Physiologic dimensions of the periodontium significant to the restorative dentist. J Periodontol 1979;50:170.
23. Oschenbein C, Maynard JG. The problem of attached gingiva in children. J Dent Children 1974;41:263.
24. Maynard JG, Oschenbein C. Mucogingival problems, prevalence and therapy in child. J Periodontol 1975;46:543.
25. Hall WB. Pure mucogingival problems. Chicago: Quintessence; 1984:132.
26. Miller PD. A classification of gingival marginal tissue recession. Int J Periodontics Restorative Dent 1985;2:8.